Laparoscopic myomectomy for a large hybrid intramural-submucosal uterine fibroid causing menorrhagia in a 35-year-old woman: a case report

Khansa Rehman[1], Hafsa Hassan Samra[2], Asad Ur Rehman[3]

Author affiliations

[1]MBBS, Allama Iqbal Medical College, Lahore

[2]MBBS, Amna Inayat Medical College, Lahore

[3]MBBS, Army Medical College, Rawalpindi

To cite: Rehman K, Samra HH, Rehman AU. Laparoscopic myomectomy for a large hybrid intramural-submucosal uterine fibroid causing menorrhagia in a 35-year-old woman: a case report. Health Innov J Eur .2026; 1:1-5.

Received [30 September 2026]

Accepted [30 October 2026]

© Author(s) (or their employer(s)) 2026. Re- use permitted under CC BY- NC. Published by Health Innovation Journal Europe.

Correspondence to

Khansa Rehman;
789khansarehman@gmail.com

1. INTRODUCTION

Uterine fibroids are the commonest benign pelvic tumors in women of reproductive age and are a leading cause of heavy menstrual bleeding, anemia and pelvic symptoms.1 Submucosal and hybrid fibroids, classified by the FIGO system, are particularly associated with menorrhagia because of their relationship to the endometrial cavity.[1] Laparoscopic myomectomy is preferred when uterine preservation is desired and is associated with less blood loss and faster recovery than open surgery in appropriately selected patients, and pre-operative correction of iron deficiency anemia is recommended before elective surgery.[2,3]

We describe a young woman with a large hybrid intramural-submucosal fibroid causing a year of menorrhagia and mild anemia, managed with pre-operative intravenous iron and laparoscopic myomectomy.

2. CASE PRESENTATION

A 35-year-old woman, para 1 (one daughter), with a history of one dilatation and evacuation in 2021 for stagnant (arrested) fetal growth, presented to the gynecology clinic of a tertiary care hospital in Karachi, Pakistan, with one year of menorrhagia and pain in the lower abdomen. Her cycles were of short duration (4–5 days) but with heavy flow. The date of her last menstrual period relative to surgery was not recorded in the available clinical notes.

Transvaginal ultrasound on 12 September 2026 showed an anteverted, bulky uterus measuring 7.8 × 5.9 × 6.6 cm with a large heterogeneous mass of 7.3 × 6.9 cm and peripheral vascularity occupying most of the uterine cavity and displacing the endometrium anteriorly, most likely an intramural fibroid. The endometrium measured 0.6 cm, visible only at the fundus and lower segment, with a streak of fluid at the lower uterine segment. Both ovaries were normal in size and echotexture, with a 1.1 × 0.8 cm follicle in the left ovary, and no free pelvic fluid.

Pelvic MRI (plain and contrast) on 19 September 2026 showed an anteverted, enlarged uterus with maximum endometrial thickness 0.5

cm. A mass involving the fundus and anterior uterine wall, measuring 7.0 × 8.0 cm, was isointense on T1-weighted images and heterogeneously hyper-intense on T2 and fat-saturated sequences, with diffuse post-contrast enhancement, causing indentation and splaying of the endometrium.

Cervix, parametrium and vagina were normal, ovaries were normal with a small follicular cyst, and there was no pelvic lymphadenopathy, free fluid or abnormal enhancement elsewhere. The mass was re-ported as most likely an intramural and submucosal uterine fibroid, FIGO hybrid type 2–5. The modest discrepancy between ultrasound (7.3 × 6.9 cm) and MRI (7.0 × 8.0 cm) measurements is within expected inter-modality variation for irregular fibroids and did not alter surgical planning.

Pre-operative blood work (8–9 September 2026) showed hemoglobin 10.2 g/dL, red cell count 3.95 × 10^{12}/L, HCT/PCV 32%, MCV 81 fL, MCH 26 pg, MCHC 32 g/dL, RDW 15.9%, WBC 4.7 × 10^{9}/L with a normal differential, and platelets 355 × 10^{9}/L; peripheral film showed normocytic, mildly hypo-chromic red cells with anisocytosis. HbA1c was 5.5% and TSH 2.68 µIU/mL, both within the normal range. Renal function and electrolytes (16 September 2026) were normal: urea 23 mg/dL, creatinine 0.80 mg/dL, sodium 136 mmol/L, potassium 4.3 mmol/L, chloride 101 mmol/L. Pre-operative echocardiography was arranged as part of routine work-up before general anesthesia; the report was not available for this review. She received a single dose of intravenous iron (Venofer, iron sucrose) two days before surgery, and one unit of packed red cells was arranged in advance but was not used.

She was admitted on 21 September 2026 under the care of the consulting gynecologist and underwent laparoscopic myomectomy on 22 September 2026 (03:30 PM–05:18 PM; duration 1 hour 48 minutes) under general anesthesia, through a supraumbilical port with three ancillary ports. Intra-operatively, the uterus was 14-week size and globular, with a fundal fibroid measuring approximately 8 × 8 cm; both fallopian tubes and the rest of the abdominal viscera appeared normal. A combined hysteroscopic laparoscopic approach was not chosen because the dominant intramural component (FIGO 2–5 hybrid) would have made complete hysteroscopic resection difficult and risked incomplete or staged removal; pure laparoscopic enucleation with layered repair was therefore preferred.

Myomectomy was performed with layered closure of the uterine defect (Figure 1), a topical hemostatic agent (Surgicel) was placed over the sutured area, and the specimen was retrieved through the umbilical port in a specimen retrieval bag. Vicryl and barbed (Stratafix) sutures were used for closure. Estimated intra-operative blood loss was not documented in the operative record.

Postoperative orders included intravenous piperacillin–tazobactam 4.5 g three times daily (administered as institutional empiric coverage rather than standard single-dose surgical prophylaxis for a clean laparoscopic procedure), intravenous paracetamol (Bofalgan 1 g) three times daily, tranexamic acid 1 g in 100 mL saline three times daily (used as institutional practice to minimize postoperative oozing after myomectomy), a Foley catheter until the following morning, diclofenac suppository twice daily, and nil by mouth until bowel sounds returned. She was dis-charged after a postoperative stay of 1.5 days on oral metronidazole, paracetamol, diclofenac and amoxicillin–clavulanate.

Histopathological examination (reported 28 September 2026) confirmed a uterine leiomyoma. The specimen consisted of multiple grayish-white irregular to nodular pieces of tissue measuring 14 × 12 cm in aggregate; the cut surface showed a whorl appearance. Representative sections demonstrated the histological features of leiomyoma.

At the time of writing, formal post-discharge

clinical follow-up data (including postoperative hemoglobin, menstrual outcome, wound healing, fertility counsel-ling or contraception plan, and repeat imaging) were not available. The patient was discharged in stable condition after an uneventful 1.5-day postoperative stay.

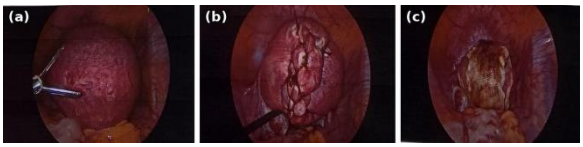

Figure 1. Intra-operative laparoscopic views. (a) Fundal fibroid prior to enucleation. (b) Layered closure of the uterine defect with interrupted and barbed sutures. (c) Completed closure with a hemostatic agent (Surgicel) placed over the sutured area. Written in-formed consent covers publication of these non-identifiable clinical images.

Table 1 Summary of key findings and management

Item	Detail
Presentation	One year of menorrhagia and lower abdominal pain; para 1, one prior D&E
Ultrasound (12 Sep 2026)	Intramural fibroid 7.3 × 6.9 cm with peripheral vascularity; uterus 7.8 × 5.9 × 6.6 cm
MRI (19 Sep 2026)	7.0 × 8.0 cm fundal/anterior wall mass, FIGO hybrid type 2–5 intramural-submucosal fibroid; endometrium splayed; no adnexal or lymph node abnormality
Hemoglobin / film	10.2 g/dL; normocytic, mildly hypochromic with anisocytosis
HbA1c / TSH	5.5% / 2.68 µIU/mL — both normal
Renal function / electrolytes	Urea 23 mg/dL, creatinine 0.80 mg/dL, Na 136, K 4.3, Cl 101 mmol/L — normal
Surgery (22 Sep 2026)	Laparoscopic myomectomy, 1 h 48 min; fundal fibroid ~8 × 8 cm from a 14-week-size uterus; layered closure with Vicryl and Stratafix; Surgicel applied; estimated blood loss not documented
Pre-operative iron	Single dose of IV iron sucrose (Venofer) 2 days pre-operatively; 1 unit packed cells arranged but not transfused
Postoperative therapy	IV piperacillin–tazobactam (institutional empiric coverage), tranexamic acid (institutional practice), Foley catheter overnight; then oral metronidazole, paracetamol, diclofenac, amoxicillin–clavulanate
Hospital stay	1.5 days postoperatively
Histopathology	Leiomyoma; aggregate specimen 14 × 12 cm; grayish-white nodular pieces with whorl cut surface (reported 28 Sep 2026)
Follow-up	Not available at time of writing (postoperative Hb, menstrual outcome, wound healing, fertility counselling)

3. DISCUSSION

This case illustrates a large hybrid intramural-sub-mucosal fibroid, which explains the year-long menorrhagia: submucosal and cavity-distorting fibroids are more closely linked to heavy bleeding than purely subserosal or intramural lesions that spare the cav-ity.[1] MRI added useful detail over ultrasound alone by confirming FIGO classification, excluding adenomyosis and lymphadenopathy, and helping to plan the surgical approach. The small difference in size estimates between ultrasound and MRI is typical and did not affect management.

Pre-operative anemia, even when mild, increases the risk of transfusion, and correcting it before elective surgery is recommended; intravenous iron allows faster correction than oral iron when the interval be-fore surgery is short.[3] In this patient, a single dose of intravenous iron sucrose was given two days before surgery. Because a clinically meaningful rise in hemoglobin cannot be expected within only two days, we do not claim that iron therapy prevented transfusion; rather, transfusion was simply not required. A unit of packed red cells had been arranged in reserve but was ultimately not used. A normal HbA1c and TSH excluded diabetes and thyroid dysfunction as contributors to her bleeding pattern. Laparoscopic myomectomy in this patient achieved removal of a large (~8 × 8 cm) fundal fibroid from a 14-week-size uterus with layered uterine closure using both conventional (Vicryl) and barbed (Stratafix) sutures,

reflecting current practice aimed at secure, efficient closure to reduce the risk of uterine dehiscence in a future pregnancy.[2] Use of a topical hemostatic agent (Surgicel) and prophylactic tranexamic acid postoperatively are consistent with local efforts to minimize bleeding after myomectomy; estimated intra-operative blood loss was not documented in the operative record, and this remains a limitation. The fact that the reserved unit of packed cells was not transfused suggests that blood loss was not clinically significant. Postoperative piperacillin–tazobactam was given as institutional empiric coverage rather than evidence-based single-dose prophylaxis for clean laparoscopic surgery; we acknowledge that this is non-standard and record it as local practice.

Comparable case series support this approach: laparoscopic myomectomy has been reported for fibroids as large as 5–18 cm, most commonly intramural or submucosal, with laparoscopy proposed as a safer alternative to hysteroscopic resection when a submucous fibroid has a large intramural extension, since this avoids the risk of an incomplete, staged hysteroscopic resection.[4,5] Correct pre-operative MRI-based FIGO classification is emphasized in this literature as important for surgical planning, since large intramural fibroids abutting the endometrium can be misclassified without it.[4]

Limitations: Histopathological confirmation is now available and confirms leiomyoma. However, formal post-discharge follow-up data (postoperative hemoglobin, menstrual outcome, wound healing, fertility counselling or contraception plan, and repeat imaging) were not available at the time of writing, so the durability of symptom relief and any late complications cannot be reported. Estimated intra-operative blood loss was not recorded; this is acknowledged as a further limitation.

Learning Points

- Menorrhagia with a large fibroid on ultrasound warrants MRI to define the FIGO type and cavity involvement, which guides both counselling and surgical planning.
- A single pre-operative dose of intravenous iron was given; transfusion was not required. A clinically meaningful hemoglobin rise cannot be expected within two days, so iron therapy should not be credited with “avoiding” transfusion.
- Layered laparoscopic closure with conventional and barbed (Stratafix) sutures, combined with a topical hemostatic agent and tranexamic acid (used as institutional practice), supports uterine preservation with a short hospital stay.
- For FIGO 2–5 hybrid fibroids with substantial intramural bulk, pure laparoscopic enucleation is of-ten preferable to a combined hysteroscopic–laparoscopic approach to avoid incomplete or staged resection.

Patient consent for publication Written informed consent was obtained from the patient for both the operative procedure and for publication of this report and any accompanying clinical images and data.

Funding No external funding was received for this work.

Competing interests The authors declare no competing interests.

Author contributions All authors were involved in the patient’s clinical care, contributed to drafting and critically revising the manuscript, and approved the final version submitted. This report follows the CARE reporting guideline.[6]

Open access This is an open access article distributed in accordance with the Creative Commons Attribution Non Commercial (CC BY- NC 4.0) license, which permits others to dis-tribute, remix, adapt, build upon this work non-commercially, and license their derivative works on different terms, provided the original work is properly cited, appropriate credit is given, any changes made indicated, and the use is non- commercial. See: https://creativecommons.org/licenses/by-nc/4.0/.

REFERENCES

1. Munro MG, Critchley HO, Broder MS, et al. FIGO classification system (PALM-COEIN) for causes of abnormal uterine bleeding in nongravid women of re-productive age. Int J Gynaecol Obstet. 2011;113:3–13. doi:10.1016/j.ijgo.2010.11.011
2. Sinha R, Hegde A, Mahajan C, et al. Laparoscopic myomectomy: do size, number, and location of the myomas form limiting factors for laparoscopic

myomectomy? J Minim Invasive Gynecol. 2008;15:292–300. doi:10.1016/j.jmig.2008.01.009
3. Muñoz M, Gómez-Ramírez S, Campos A, et al. Pre-operative anaemia: prevalence, consequences and approaches to management. Blood Transfus. 2015;13:370–9. doi:10.2450/2015.0014-15
4. Dubuisson JB, Fauconnier A, Fourchotte V, et al. Laparoscopic myomectomy: predicting the risk of conversion to an open procedure. Hum Reprod. 2001;16:1726–31. doi:10.1093/humrep/16.8.1726
5. Saccardi C, Gizzo S, Noventa M, et al. Limits and complications of laparoscopic myomectomy: which are the best predictors? A large cohort single-center experience. Arch gynecol obstet. 2014; 290(5): 951–956. https://doi.org/10.1007/s00404-014-3289-2
6. Gagnier JJ, Kienle G, Altman DG, et al. The CARE guidelines: consensus-based clinical case reporting guideline development. Glob Adv Health Med. 2013;7:223. doi:10.7453/gahmj.2013.008